

## Vitamin B12 Deficiency Mimicking Acute Leukemia in a Child

Hikmet Gulsah Tanyildiz\*, Baris Malbora, Sule Yesil, Sibel Akpinar Tekgunduz, Mehmet Onur Candir, Ceyhun Bozkurt and Gurses Sahin

Dr. Sami Ulus Research and Training Hospital of Women's and Children's Health and Diseases, Ankara, Turkey

### Abstract

Tanyildiz HG, Malbora B, Yesil S, Candir MO, Bozkurt C, Sahin G. Vitamin B12 Deficiency Mimicking Acute Leukemia in a Child. Deficiency of vitamin B12 is an important cause of megaloblastic anemia and bone marrow depression. Morphological and functional changes in bone marrow are observed related with vitamin B12 deficiency. Most importantly dysplastic changes can be mistaken as myelodysplastic syndrome or acute leukemia. In adult cases of vitamin B12 deficiencies mimicking acute leukemia were reported. Our case is an alerting example of vitamin B12 deficiency in children mimicking acute leukemia with dysplastic findings.

**Keywords:** Vitamin B12 deficiency; Acute myeloblastic leukemia; Childhood treatment

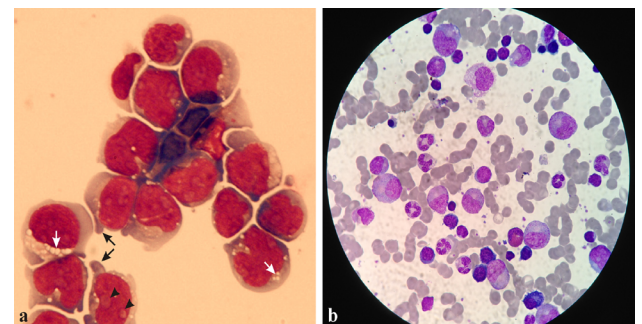
### Introduction

Deficiency of vitamin B12 is an important cause of megaloblastic anemia and bone marrow depression. Common symptoms of anemia like fatigue, pallor, anorexia and neurological disorders such as dementia, ataxia and neuropathies are clinical manifestations of vitamin B12 deficiency [1]. Pancytopenia can be seen as a result of ineffective DNA synthesis. Increased levels of Mean Corpuscular Volume (MCV), hyper segmentation of neutrophils, reticulocytosis, leukopenia and thrombocytopenia are other hematological findings [2]. Hyper cellularity, blastic differentiations and chromosomal abnormalities in cases presented with pancytopenia can be misdiagnosed with myelodysplastic syndrome or acute leukemia by clinicians. In adults cases of vitamin B12 deficiencies mimicking acute leukemia were reported. However, there is no case has been reported in childhood. We present a patient referred to our hospital as Acute Myeloblastic Leukemia (AML) previously and improved outcomes in terms of blastic changes on peripheral blood smear and pancytopenia after vitamin B12 supplementation.

### Case Report

Fifteen years old male patient presented to our hospital because of dizziness started 3 months ago in addition to progressive fatigue and weakness for the past month. Weight loss and night sweating were also noted. Physical examination revealed pallor of skin and laboratory results were consisted with pancytopenia (hemoglobin [Hb] 5.1 g/dL, MCV 80 fL, MCH 21.6 pg, MCHC 31 g/dL, RDW 22%, leukocyte  $1.5 \times 10^9/L$ , neutrophil  $0.47 \times 10^9/L$ , thrombocyte  $72 \times 10^9/L$ ). He was a vegetarian. Peripheral blood smear revealed that 32% neutrophil, 56% lymphocyte, 4% monocyte, 8% eosinophil besides 4 normoblast. Macrocytosis, anisocytosis, polychromasia and neutrophil hypersegmentation were seen. Biochemical results including total bilirubin, 2.2 mg/dL; direct bilirubin, 0.3 mg/dL; AST, 193 U/L; ALT, 87 U/L; LDH, 10,148 U/L; haptoglobin, 10 mg/dL (36-195) and reticulocyte 3% were identified. Hepatitis A, B, and C virus, HIV, EBV, CMV, and Parvovirus serology were negative and vitamin B12 levels were decreased (80 pg/mL; normal range 200-1510). Folic acid, methylmalonic acid, urine and blood amino acid levels were in normal range but homocystein level was increased (139  $\mu\text{mol/L}$ ; normal range, 0-12). Examination of bone marrow aspiration showed hypercellular. Dysplastic normoblasts with double nucleus and megaloblastic erythrocytes were seen. Promyelocyte 2%, myelocyte 17%, metamyelocyte 27%, neutrophil 16%, lymphocyte 6%, monocyte 8%, blast 24% (the blebbed monoblastoid cells are characterized by uncondensed, immature chromatin with prominent nucleoli and vacuolated cytoplasm).

vacuolated cytoplasm), early erythroblast count 73, normoblast count 28 (Figure 1a). Myeloperoxidase was negative immunohistochemically. Flow-cytometric (tdt was negative) and cytogenetic analysis were unremarkable in terms of acute leukemia. We performed FISH for monosomy 7 and del 7q differential diagnosis of MDS. We thought that dysplastic changes were related with vitamin B12 deficiency and we also started cyanocobalamine. In first week of the treatment laboratory results were Hb 8.6 g/dL, leukocyte  $2.3 \times 10^9/L$ , neutrophil  $0.58 \times 10^9/L$ , thrombocyte  $139 \times 10^9/L$ , LDH 1997 U/L, homocysteine 14.6  $\mu\text{mol/L}$ , ferritin 27.3 ng/mL and in third month of the treatment the same laboratory parameters were Hb 14.1 g/dL, leukocyte  $6.4 \times 10^9/L$ , neutrophil  $3.81 \times 10^9/L$ , thrombocyte  $307 \times 10^9/L$ , homocysteine 13.7  $\mu\text{mol/L}$ , ferritin 5.7 ng/mL, LDH 134 U/L. According to these results 6 mg/kg oral ferrous sulfate was started (Table 1 and Figure 1b). We performed second bone marrow aspiration and saw the disappearance of blasts. After B12 replacement with performed bone marrow aspiration we excluded the co-presence of MDS (Figure 2).



**Figure 1:** a. Bone marrow aspiration shows that the blebbed monoblastoid cells (black arrows) are characterized by uncondensed, immature chromatin with prominent nucleoli (black arrowheads) and vacuolated cytoplasm (white arrows). b. After replacement of B12 treatment, disappearance of abnormal cells.

**\*Corresponding author:** Hikmet Gülşah Tanyıldız, Dr. Sami Ulus Research and Training Hospital of Women's and Children's Health and Diseases, Ankara, Turkey, Tel: +90 312 305 60 61; Fax: +90 312 317 03 53, E-mail: [g\\_oktay4910@yahoo.com](mailto:g_oktay4910@yahoo.com)

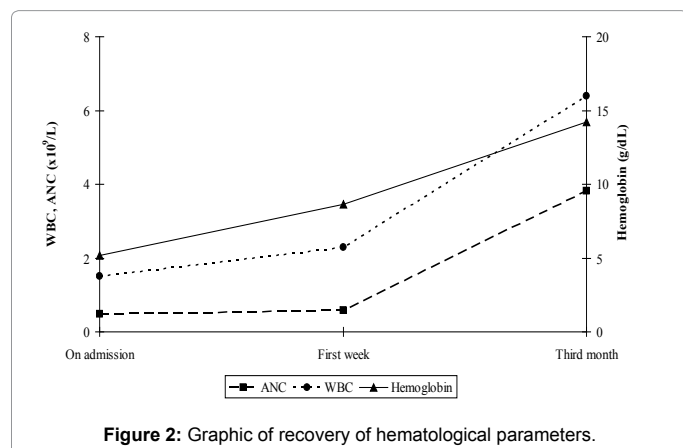
**Received** September 16, 2014; **Accepted** October 06, 2014; **Published** October 12, 2014

**Citation:** Tanyildiz HG, Malbora B, Yesil S, Tekgunduz SA, Candir MO, et al. (2014) Vitamin B12 Deficiency Mimicking Acute Leukemia in a Child. J Clin Case Rep 4: 430. doi:10.4172/2165-7920.1000430

**Copyright:** © 2014 Tanyildiz HG, et al. This is an open-access article distributed under the terms of the Creative Commons Attribution License, which permits unrestricted use, distribution, and reproduction in any medium, provided the original author and source are credited.

Duration	Hb (g/dL)	WBC ( $\times 10^9/L$ )	Neutrophil ( $\times 10^9/L$ )	Platelet ( $\times 10^9/L$ )	LDH (U/L)	Homocysteine ( $\mu\text{mol/L}$ )	Ferritin (ng/mL)
On admission	5.19	1.5	0.48	71	10148	139	100.6
First week of treatment	8.64	2.3	0.58	139	1997	14.6	27.3
Third month of treatment	14.21	6.4	3.81	307	134	13.7	5.7

**Table 1:** Laboratory values on diagnosis, first week and third month of vitamin B12 treatment.



**Figure 2:** Graphic of recovery of hematological parameters.

## Discussion

In adults, although there are many case reports about vitamin B12 deficiency mimicking acute leukemia or myelodysplastic syndrome (MDS), this situation is uncommon in childhood. Randhawa et al. [3]. reported 66 years old male pancytopenia patient presented with fatigue and pallor. Maturation of precursor erythroid cells was discontinued and ratio of myeloid/erythroid was decreased. Flow-cytometry results of bone marrow were inconclusive about acute leukemia and lymphoproliferative malignancy also monosomy 5/del(5q), monosomy 7/del (7q) and trisomy 8 were negative. Although vitamin B12 level was low and biopsy of bone marrow result was consistent with MDS, pancytopenia and pernicious anemia were improved by vitamin B12 supplementation.

Aitelli et al. [4] reported two cases of vitamin B12 deficiency mimicking acute leukemia and AML cytogenetic results were not consist with acute leukemia. Clinical findings were improved by vitamin B12 supplementation. The second pancytopenia case was considered initially as MDS and AML because of having increased numbers of blasts and LDH levels with hyper cellular bone marrow but normal results of flow-cytometry and cytogenetic analysis accompanying

decreased levels of vitamin B12 confirmed diagnosis of pernicious anemia. In our pancytopenic case, vitamin B12 levels were decreased and blastic differentiations mimicking AML were observed also flow-cytometry and cytogenetic results were in normal range. Vitamin B12 plays an important role in synthesis of DNA and cell division so its deficiency causes megaloblastic changes in bone marrow. Atypical presentations challenging for diagnosis, bone marrow examination can be used but clinicians must be alert about blastic differentiations mimicking acute leukemia [5].

In conclusion, vitamin B12 deficiency should be considered as a differential diagnosis in all patients suspected with MDS and AML. Methylation of homocysteine to methionine is decreased and levels of homocysteine is increased in case of vitamin B12 deficiency. According to this knowledge increased levels of homocysteine may support vitamin B12 deficiency in laboratory [6]. Vitamin B12 supplementation causes normalization of homocysteine levels. Suspicious of MDS or leukemia measurement of vitamin B12 and homocystein levels would be better before performing bone marrow biopsy, flow-cytometry and cytogenetic analysis. After replacement of B12 treatment bone marrow should be checked for disappearance of blasts and accompanied MDS with blasts.

## References

1. Stabler SP (2013) Clinical practice. Vitamin B12 deficiency. N Engl J Med 368: 149-160.
2. Watkins D, Whitehead M, Rosenblatt DS (2009) Megaloblastic anemia. Hematology of Infancy and Childhood (7<sup>th</sup> edn), Saunders Elsevier.
3. Randhawa J, Ondrejka SL, Setrakian S, Taylor H (2013) What should I know before ordering a bone marrow aspiration/biopsy in patients with vitamin B12 deficiency? BMJ Case Rep 2013.
4. Aitelli C, Wasson L, Page R (2004) Pernicious anemia: presentations mimicking acute leukemia. South Med J 97: 295-297.
5. Dokal IS, Cox TM, Galton DA (1990) Vitamin B-12 and folate deficiency presenting as leukaemia. BMJ 300: 1263-1264.
6. Vogel T, Dali-Youcef N, Kaltenbach G, Andres E (2009) Homocysteine, vitamin B12, folate and cognitive functions: a systematic and critical review of the literature. Int J Clin Pract 63: 1061-1067.

**Citation:** Tanyildiz HG, Malbora B, Yesil S, Tekgunduz SA, Candir MO, et al. (2014) Vitamin B12 Deficiency Mimicking Acute Leukemia in a Child. J Clin Case Rep 4: 430. doi:10.4172/2165-7920.1000430

## Submit your next manuscript and get advantages of OMICS Group submissions

### Unique features:

- User friendly/feasible website-translation of your paper to 50 world's leading languages
- Audio Version of published paper
- Digital articles to share and explore

### Special features:

- 350 Open Access Journals
- 30,000 editorial team
- 21 days rapid review process
- Quality and quick editorial, review and publication processing
- Indexing at PubMed (partial), Scopus, EBSCO, Index Copernicus and Google Scholar etc
- Sharing Option: Social Networking Enabled
- Authors, Reviewers and Editors rewarded with online Scientific Credits
- Better discount for your subsequent articles

Submit your manuscript at: <http://www.omicsonline.org/submission>